

---

# *Vasectomy reversal: new techniques and role in the era of intracytoplasmic sperm injection*

Edward Karpman, MD, Daniel H. Williams IV, MD, Larry I. Lipshultz, MD

Scott Department of Urology, Baylor College of Medicine, Houston, Texas, USA

---

KARPMAN E, WILLIAMS DH, LIPSHULTZ LI. Vasectomy reversal: new techniques and role in the era of intracytoplasmic sperm injection. *The Canadian Journal of Urology*. 2006;13(Supplement 1):0000-0000.

*The growing popularity of vasectomy as a primary form of birth control has also created an increasing demand for vasectomy reversal (VR). The advent of IVF with intracytoplasmic sperm injection after sperm retrieval has given couples an alternative to traditional VR. Although VR remains the most cost-effective and natural way to conceive after vasectomy, competing interests and market pressures have encouraged the development of this*

*assisted reproductive technique (ART). The success of VR is dependent on several variables. The length of time since vasectomy and an individual surgeon's experience appear to be the most significant factors and are equally important. The success of this procedure is highly contingent on adherence to strict surgical principles of creating a water-tight, tension-free anastomosis, along with the appropriate decision whether to perform either a vasovasostomy or epididymovasostomy at the time of VR.*

**Key Words:** vasectomy reversal, vasovasostomy, intracytoplasmic sperm injection

---

## Introduction

The use of vasectomy as a permanent form of contraception has grown to be the most popular form of male sterilization in the United States with approximately 500,000 cases performed annually.<sup>1</sup> The ease and reliability of the procedure has added to its appeal. Reasons for requesting a vasectomy reversal (VR) include re-marriage, loss of a child, desire for further fertility and chronic testicular pain. Regardless of the duration since vasectomy, sperm production remains relatively normal.

The choice of VR includes vasovasostomy (VV) or epididymovasostomy (EV). The decision to proceed with either procedure is dependent on certain intraoperative findings. The presence of sperm and the quality of fluid in the vas deferens are important predictors of a successful VV. The finding of intravascular sperm has been shown to be closely correlated to the duration of the obstructive interval, the presence of a sperm granuloma at the vasectomy site and the length of the testicular vas deferens.<sup>2-5</sup> The role of anti-sperm antibodies (ASA) in having a successful pregnancy after VR is controversial.<sup>6</sup> The majority of patients after vasectomy and VR have ASA and predicting prospectively which of these patients will have difficulty conceiving is not possible. Regardless of whether a VV or EV is performed, the success

---

Address correspondence to Dr. Larry I. Lipshultz, Scott Department of Urology, Baylor College of Medicine, One Baylor Plaza, Houston, Texas 77030 USA

rate for VR using a microsurgical technique is very high amongst experienced surgeons with appropriate assessment of intraoperative vasal fluid characteristics.

The introduction of in vitro fertilization and intracytoplasmic sperm injection (IVF/ICSI) has added an alternative to VR for couples desiring conception after vasectomy.<sup>7</sup> Epididymal sperm aspiration and injection of a single sperm into an oocyte is possible with reasonable success rates.<sup>8</sup> Some infertility experts have argued that IVF/ICSI should be preferentially offered to couples, bypassing surgical reconstruction and disregarding the additional costs and risks that are associated with IVF/ICSI. The outcomes and risks associated with IVF/ICSI are beyond the scope of this paper and a more detailed discussion on this subject is available.<sup>9</sup> A discussion of the costs related to the various ways of achieving pregnancy after vasectomy is important at this time because it is usually the financial responsibility of the couple and an integral part of their decision making process.

### Technique of microsurgical vasovasostomy (2-layer)

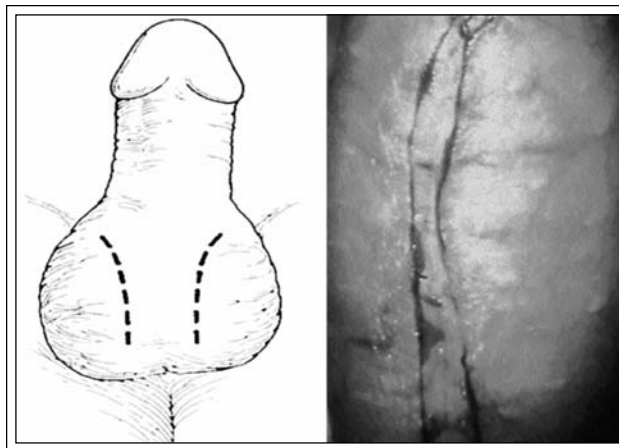
The technique for VV can be divided into four phases: incision and delivery of the testicle, isolating the vasa, fluid assessment and anastomosis. All patients are offered sperm cryopreservation at the time of VR if motile sperm are identified.

#### *Incision and delivery*

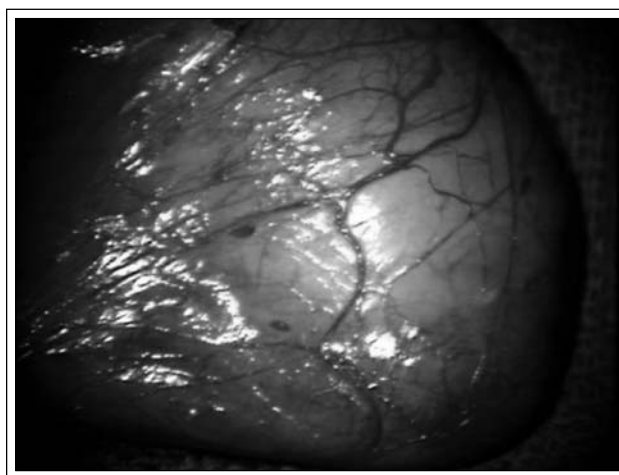
A vertical incision is made in the hemiscrotum through the skin and Dartos fascia layer, Figure 1. The testicle along with the tunica vaginalis is manually released from its surrounding tissues. The testicle is then delivered with the intact tunica vaginalis, Figure 2.

#### *Isolating the vas deferens*

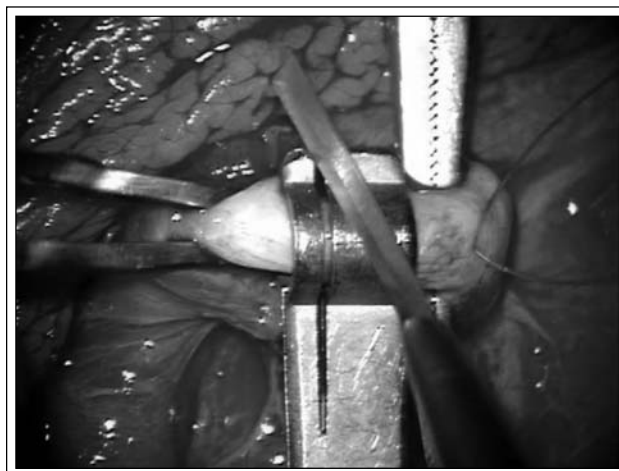
The previous vasectomy site is identified and the testicular end of the vas deferens is dissected out. Typically, this is done using a fine pair of scissors, a Jacobson clamp and a Bishop forceps. Care is taken not to devascularize the vas by removing all of the surrounding adventitial tissue. Once the vas has been mobilized, a 5-0 chromic stay suture is placed in the muscular wall of the vas to prevent retraction. A number 3 or 4 nerve holder stabilizes the vas while a Dennis blade is used to transect the vas at a 90 degree angle, Figure 3.



**Figure 1.** Vertical hemiscrotal incisions.



**Figure 2.** Testicle delivered with tunica vaginalis intact.



**Figure 3.** Transection of the testicular end of the vas deferens.

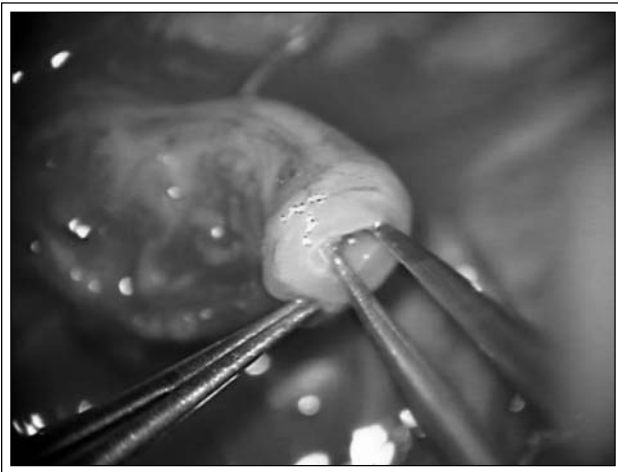
TABLE 1. Decision analysis for performing vasectomy reversal

Sperm quality	Comments	Reversal technique
Whole sperm	+/- motile	VV
None	Clear fluid, <5 yrs since vasectomy	VV
Heads and tails	<10 yrs since vasectomy	VV
Heads	Thick fluid	VV or EV
None	Thick, creamy/pasty fluid	EV

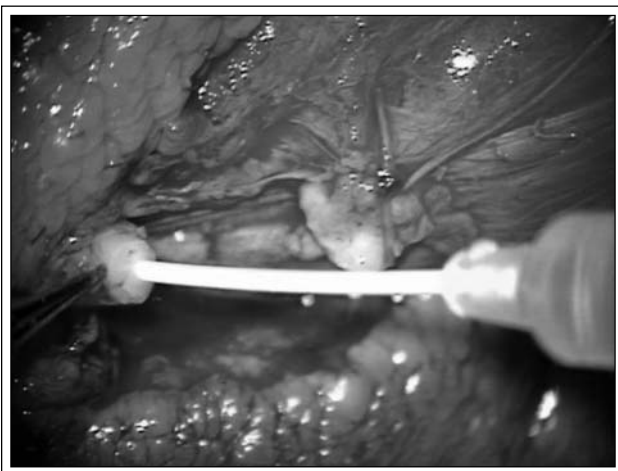
VV = vasovasostomy; EV = epididymovasostomy

### Fluid assessment

The fluid from the testicular end of the vas deferens is inspected grossly and with light microscopy. The decision to proceed with VV or EV is made intra-



**Figure 4.** Dilating the abdominal end of the vas deferens.

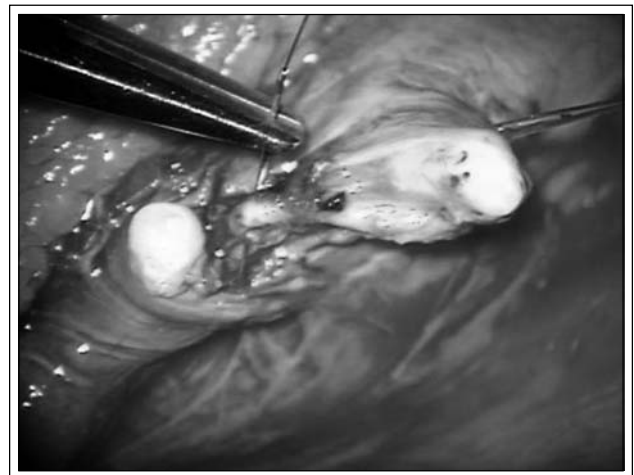


**Figure 5.** Flushing the abdominal vas deferens.

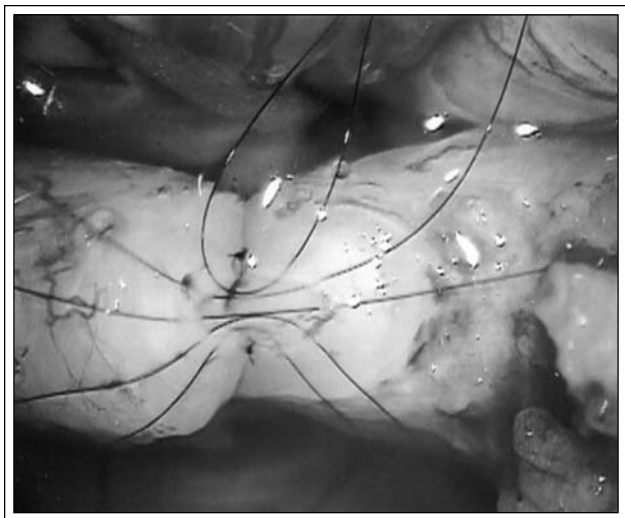
operatively after assessment of the intravasal sperm and fluid quality, Table 1. When the decision to proceed with VV is made, the abdominal end of the vas is isolated in similar fashion to the testicular end, but above the vasectomy site. The abdominal end of the vas is then dilated with a fine jeweler's forceps, Figure 4. The vas is intubated with a 25 gauge angiocath syringe and flushed with sterile water to confirm patency, Figure 5.

### Anastomosis

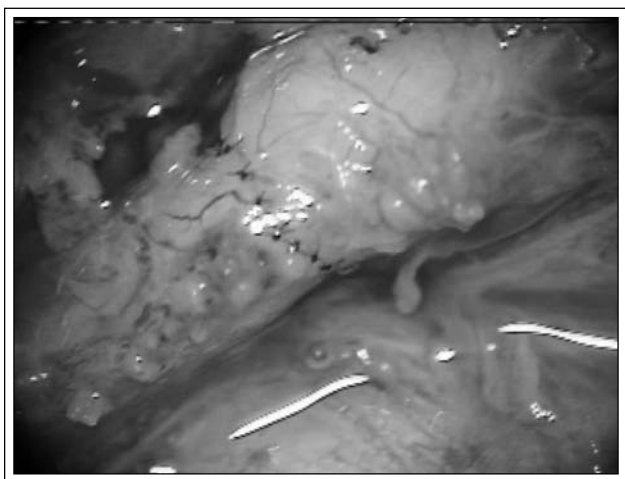
The two cut ends of the vas deferens are re-approximated by placing a 5-0 PDS suture in the peri-vasal tissue and tying the peri-vasal tissue together, Figure 6. This maneuver releases any tension from the ends of the vas deferens. Prior to creating the anastomosis, a fine-tip marking pen is used to mark the 6 o'clock position on both vasal ends. A 9-zero nylon suture is used to re-appose the serosa layer at the 5, 6 and 7 o'clock positions. Next, double armed 10-zero nylon sutures are placed in the vasal mucosa at similar 5, 6 and 7 o'clock positions and tied. Five



**Figure 6.** Re-approximating the vasa.



**Figure 7.** Web-like appearance of mucosal suture placement.



**Figure 8.** Completed anastomosis.

additional double armed 10-zero nylon sutures are then placed at the 1,3,9,11 and 12 o'clock positions of the vasal mucosa prior to tying, creating a web-like appearance, Figure 7. The mucosal sutures are then tied to provide a water-tight mucosal apposition. An adequate number of 9-zero nylon sutures are placed in the serosa to create a tension-free anastomosis, Figure 8.

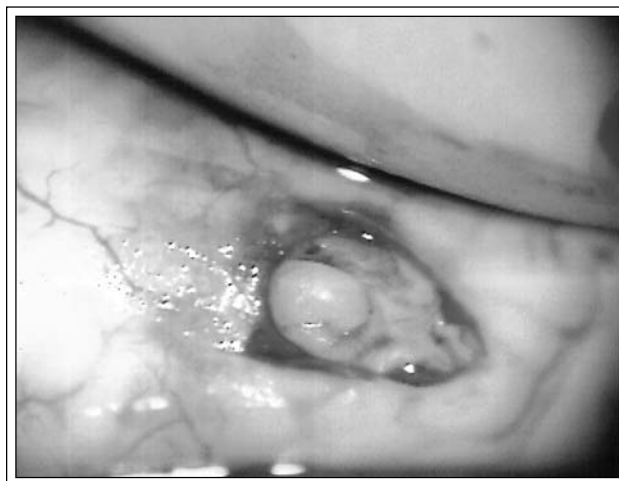
#### *Technique of microsurgical epididymovasostomy (end-to-side)*

The pre-operative evaluation and set-up is similar to the VV procedure. Whether an EV is anticipated pre-operatively or decided on intra-operatively, the steps are the same up to and including inspection of the fluid

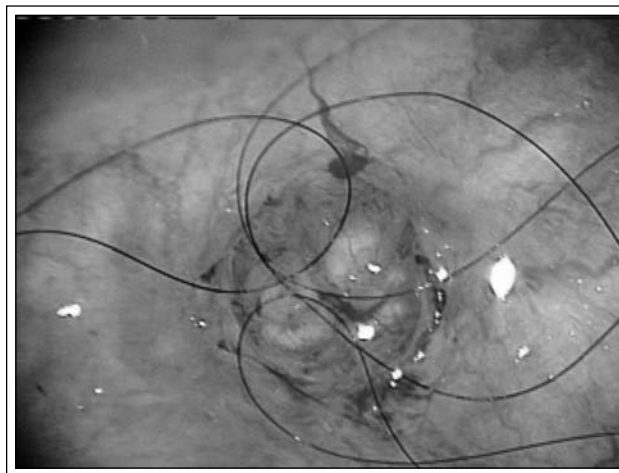
from the testicular end of the vas deferens.

Once the decision to perform an EV has been made, a long segment of the abdominal vas is mobilized. This segment must be longer than in the VV procedure in order to bridge the gap created by the vasectomy.

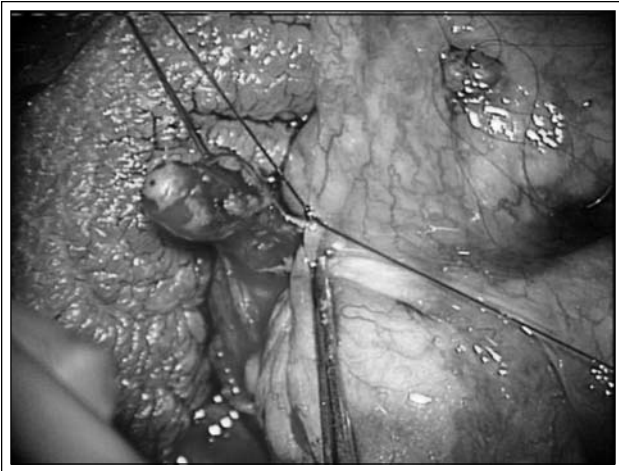
The tunica vaginalis is opened, delivering the testicle and epididymis. The epididymis is inspected, and an area proximal to the presumed site of obstruction is identified. The tunic of the epididymis is opened using a pair of dissecting micro scissors. Careful dissection of a single epididymal tubule with a pair of fine jeweler's forceps is accomplished, Figure 9. Methylene blue is used to better outline the single tubule. We then use the dissecting micro scissors to tangentially cut a circular opening at the apex of the



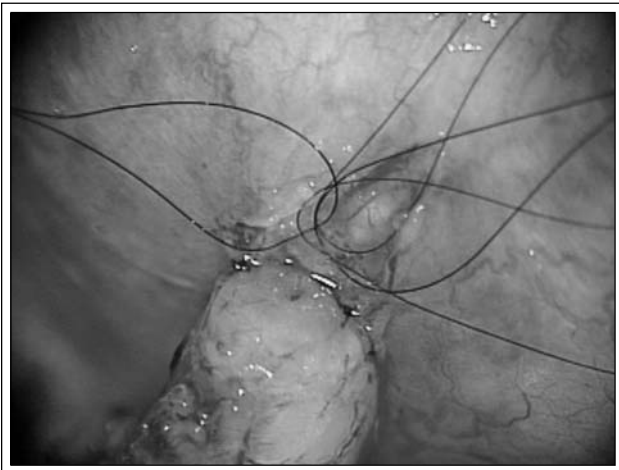
**Figure 9.** Isolated epididymal tubule.



**Figure 10.** Four, 10-zero nylon sutures are used to create the mucosal anastomosis.



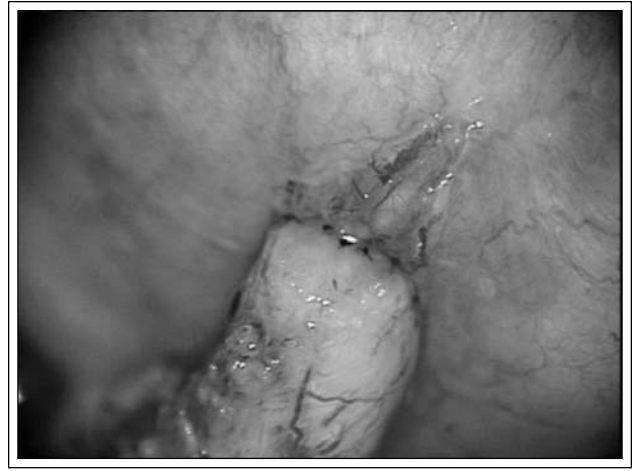**Figure 11.** Securing the abdominal vas deferens to epididymal tunic.



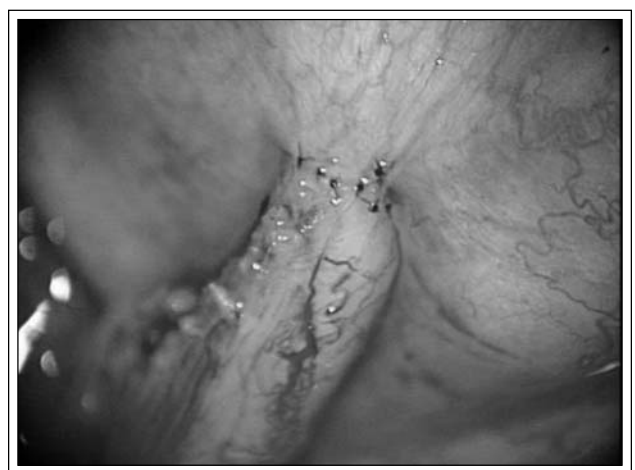**Figure 12.** Serosal edge of vas deferens secured to epididymal tunic at 5, 6 and 7 o'clock.

desired tubule. The fluid from the epididymal tubule is collected using a 25 gauge angiocath syringe and plated on a slide. If whole sperm are not identified, then a similar exploration is performed on the epididymis more proximal to this location. If motile sperm are identified and if the patient desires, sperm is harvested at this time for cryopreservation. After the tubulotomy is completed and sperm are confirmed on light microscopy, we then carefully place double-armed 10-zero nylon sutures at the 3, 6, 9 and 12 o'clock positions in the lumen of the epididymal tubule, Figure 10.

Next, the previously mobilized abdominal end of the vas deferens is brought through an opening created in the tunica vaginalis. The adventitia of the vas is secured to the tunic of the epididymis



**Figure 13.** Appearance of completed mucosal anastomosis (inner layer).



**Figure 14.** Appearance of completed serosa-tunic anastomosis (outer layer).

using a 5-zero PDS suture at a point 1 cm below the cut edge, Figure 11. A 7-zero PDS suture can be placed in a similar manner more distally on the vas deferens if necessary to further secure it to the epididymal tunic. The serosal edge of the vas is then secured to the opened edge of the epididymal tunic using 9-zero nylon sutures at the 5, 6 and 7 o'clock positions, Figure 12. The previously placed double armed 10-zero nylon sutures are individually placed through corresponding points in the vasal mucosa. Tying these sutures creates a water-tight mucosal apposition between the vas and epididymal tubule, Figure 13. Additional 9-zero nylon sutures are placed through the serosal edge of the vas deferens and the epididymal tunica, releasing tension on the mucosal sutures, Figure 14.

The testicle is then replaced inside the tunica vaginalis and the tunic closed.

## Cost analysis

The success of sperm aspiration and IVF/ICSI has prompted some fertility experts to advocate bypassing surgical reconstruction for couples desiring conception after vasectomy. The costs of IVF/ICSI must take into consideration numerous factors including the evaluation of the patient, the need for expensive fertility drugs to cause the eggs to mature, surgical intervention to retrieve the eggs, fertilizing and incubating the embryos, the risk of multiple gestation pregnancies, complications associated with pre-term labor, prolonged hospitalization, retrieving and processing the sperm and finally, the desire for future children. The success of each cycle of IVF/ICSI is equally important when considering the overall cost of this therapy. Taking the cost of most of these factors into account and dividing it by the take-home baby rate, Neumann et al reported the average cost for a successful first cycle of conventional IVF to be \$66,667.<sup>10</sup> In the best case scenario (i.e. a female patient with tubal factor infertility), the cost was as low as \$50,000 per delivery for the first cycle. However in the older female (>40 years) coupled with a male-factor, the cost rose to \$160,000 for the first cycle.

A cost comparison between VR and sperm aspiration with IVF/ICSI further highlights the cost differences between the two approaches. A recent report showed that the cost per delivery after VR was \$25,475 with a delivery rate of 47%.<sup>11</sup> This is in contrast to the cost of sperm retrieval and IVF/ICSI at an average cost of \$72,521 with a delivery rate of 33%. Other studies have looked at the cost of VR in the setting of requiring the more complex EV, re-do VR or in couples with an older female partner.<sup>7,12,13</sup> The findings in all of these studies were similar in that it is more cost effective for VR as opposed to proceeding to sperm aspiration and IVF/ICSI.

## Conclusion

Vasectomy reversal remains the most cost-effective strategy for achieving conception after vasectomy. The use of a microsurgical technique allows for highly successful rates of vasectomy reversal either when doing a vasovasostomy or the technically more challenging epididymovasostomy. A successful VR is highly contingent on the appropriate decision for a VV or EV at the time of surgery. The presence or absence of sperm and the

quality of the fluid from the testicular vas deferens are the best predictors of which type of surgery (i.e. VV or EV) should be performed. □

---

## References

---

1. Marquette CM, Koonin LM, Antarsh L, Gargiullo PM, Smith JC. Vasectomy in the United States, 1991. *Am J Public Health* May 1995;85(5):644-649.
2. Belker AM, Thomas AJ, Jr., Fuchs EF, Konnak JW, Sharlip ID. Results of 1,469 microsurgical vasectomy reversals by the Vasovasostomy Study Group. *J Urol* Mar 1991;145(3):505-511.
3. Belker AM, Konnak JW, Sharlip ID, Thomas AJ, Jr. Intraoperative observations during vasovasostomy in 334 patients. *J Urol* Mar 1983;129(3):524-527.
4. Witt MA, Heron S, Lipshultz LI. The post-vasectomy length of the testicular vasal remnant: a predictor of surgical outcome in microscopic vasectomy reversal. *J Urol* Apr 1994;151(4):892-894.
5. Sharlip ID, Belker AM, Konnak JW, Thomas AJ, Jr. Relationship of gross appearance of vas fluid during vasovasostomy to sperm quality, obstructive interval and sperm granuloma. *J Urol* Apr 1984;131(4):681-683.
6. Cookson MS, Witt MA, Kimball KT, Grantmyre JE, Lipshultz LI. Can semen analysis predict the presence of antisperm antibodies in patients with primary infertility? *World J Urol* 1995;13(5):318-322.
7. Kolettis PN, Thomas AJ, Jr. Vasoepididymostomy for vasectomy reversal: a critical assessment in the era of intracytoplasmic sperm injection. *J Urol* Aug 1997;158(2):467-470.
8. CDC, American Society for Reproductive Medicine aSfART. 2002 assisted reproductive technology success rates (<http://www.cdc.gov/reproductivehealth/ART02/index.htm>).
9. Karpman E, Williams DH, Lipshultz LI. IVF and ICSI in Male Infertility: Update on Outcomes, Risks, and Costs. *ScientificWorldJournal* Nov 16 2005;5:922-932.
10. Neumann PJ, Gharib SD, Weinstein MC. The cost of a successful delivery with in vitro fertilization. *N Engl J Med* Jul 28 1994;331(4):239-243.
11. Pavlovich CP, Schlegel PN. Fertility options after vasectomy: a cost-effectiveness analysis. *Fertil Steril* Jan 1997;67(1):133-141.
12. Berger RE. Triangulation end-to-side vasoepididymostomy. *J Urol* Jun 1998;159(6):1951-1953.
13. Donovan JF, Jr., DiBaise M, Sparks AE, Kessler J, Sandlow JL. Comparison of microscopic epididymal sperm aspiration and intracytoplasmic sperm injection/in-vitro fertilization with repeat microscopic reconstruction following vasectomy: is second attempt vas reversal worth the effort? *Hum Reprod* Feb 1998;13(2):387-393.