
Varicocele: surgical techniques in 2005

Daniel H. Williams, MD, Edward Karpman, MD, Larry I. Lipshultz, MD

Department of Urology, Baylor College of Medicine, Houston, Texas, USA

WILLIAMS DH, KARPMAN E, LIPSHULTZ LI.
Varicocele: surgical techniques in 2005. *The Canadian Journal of Urology*. 2006;13(Supplement 1):0000-0000.

Varicocele is the most common diagnosis in men presenting to fertility clinics. Traditional indications for correction of varicocele include scrotal pain, testicular atrophy, and infertility without other apparent causes. Adolescent varicocele correction is indicated if pain or testicular growth retardation is present. Following varicocelectomy most studies report improved semen parameters, increased serum testosterone, improvement in functional sperm defects, and the return of motile sperm in selected azoospermic men. However, conflicting data exists on pregnancy and fertility outcomes. Consistent data supporting the effectiveness of repairing subclinical varicoceles is sparse. Most authors generally agree that the primary effect of varicoceles is on testicular temperature. Varicoceles are diagnosed primarily by

physical examination. Radiographic assessments are helpful when physical examination is inconclusive or when further objective documentation of a patient's condition is necessary. Several surgical approaches to varicocelectomy exist, each with its own advantages and drawbacks. We prefer the inguinal approach to varicocelectomy, except when there is a history of previous inguinal surgery. In such cases, the subinguinal technique is employed. Routine use of an operating microscope and a micro Doppler probe affords easier identification of vessels and lymphatics. Varicocele remains the most surgically treatable form of male infertility. Knowing the correct techniques of diagnosis and surgical correction ensures the best chance of successful outcomes in terms of post-operative morbidity, improved semen parameters, and pregnancy rates.

Key Words:

Varicocele is the most common diagnosis in men presenting to fertility clinics, Table 1.¹ The incidence of varicocele in the general population has been reported to be 13.4% or greater, whereas 37% or more of infertile men have been noted to have varicoceles.² The World Health Organization (WHO) investigated the influence of varicocele on fertility in men presenting to infertility clinics and concluded that varicocele is clearly associated with impairment of testicular function and infertility.³

Traditional indications for correction of varicocele include scrotal pain, testicular atrophy, and infertility without other apparent causes. Controversial indications include adolescent varicoceles, subclinical varicoceles, azoospermia, and functional sperm defects.

Adolescent varicoceles

Varicoceles are present in approximately 15% of adolescent males (2.7 million individuals). Routine correction for fertility is not always indicated, since it is not cost effective, fertility will not necessarily be affected, and it is often inappropriate to ask for semen analyses in this age group. However, repair of

Address correspondence to Dr. Larry I. Lipshultz, Scott Department of Urology, Baylor College of Medicine, One Baylor Plaza, Houston, Texas 77030 USA

TABLE 1. Distribution of final diagnostic categories found in male fertility clinic¹

Category	Number	%
Varicocele	603	42.2
Idiopathic	324	22.7
Obstruction	205	14.3
Normal/female factor	119	7.9
Cryptorchidism	49	3.4
Immunological	37	2.6
Ejaculatory dysfunction	18	1.3
Testicular failure	18	1.3
Drug/radiation	16	1.1
Endocrinopathy	16	1.1
Others (all <1.0%)	31	2.1
Total	1430	100.0

¹Sigman M, Infertility in the Male, 3rd ed, 1997.

varicoceles is indicated in adolescents who exhibit ipsilateral pain or hypotrophy (atrophy). Catch up growth has been consistently reported in multiple studies.⁴⁻⁹ Additionally, improved semen quality, but not pregnancy, has been demonstrated.¹⁰⁻¹² Thus, there is no scientific indication for correction of all adolescent varicoceles, since repair would be unnecessary 86% of the time.^{3,13} Adolescent varicocele correction is indicated if pain or testicular growth retardation is present.

Azoospermia

One of the first clinical reports of varicocele repair in an azoospermic patient was by Tulloch in 1955.¹⁴ He demonstrated that varicocele repair resulted in restoration of spermatogenesis and subsequent pregnancy in an initially azoospermic patient. Since that time, multiple studies have documented the return of motile sperm following varicolectomy in azoospermic men with clinical evidence of varicocele. Reported rates range from 21%-55%, with the best chance of success occurring when sperm or spermatids are present on pre-op testis biopsy.¹⁵⁻¹⁷

Functional sperm defects

Varicolectomy has been shown to improve several specific functional sperm defects. Following

varicocele repair, improvements have been seen in the sperm penetration assay (SPA)¹⁸ strict morphology quantification,¹⁹ oxidant determination (ROS),²⁰ and DNA fragmentation.²¹ Additionally, serum testosterone has been reported to increase following repair of varicoceles.^{22,23} Furthermore, following varicocele repair, pregnancy rates increase with intrauterine insemination (IUI) despite the absence of significant changes in gross semen analyses.²⁴ It is postulated that an improved functional factor not measured on routine semen analysis may explain this increased success.

Subclinical varicoceles

The management of subclinical varicoceles remains a dilemma. No consensus exists on the definition of this non-palpable entity, as there is no agreement on size. Most authors agree that subclinical varicoceles are varicoceles less than 3 mm in diameter.²⁵ These lesions typically are found only by imaging. Imaging modalities used to detect varicoceles include doppler, ultrasound, and thermography.

Consistent data supporting the effectiveness of repairing subclinical varicoceles is sparse. The effects on spermatogenesis are unknown, and there has been no proven effect on pregnancy.²⁶ No improvement on semen analysis has been shown following repair of these lesions.²⁷ In a meta-analysis study, there was inconsistent improvement in semen parameters and pregnancy rates following the repair of subclinical varicoceles.²⁸ Large, randomized, prospective studies are required to further investigate this entity and its role in male factor infertility. Currently, at our institution, we do not to operate on these lesions.

Pathophysiology

Numerous theories have been proposed regarding the mechanism of effect of varicoceles. Some of these include elevated testicular temperature, pressure secondary to reflux effect, oxygen deprivation, and accumulation of toxins. Most authors generally agree that the primary effect of varicoceles is on testicular temperature. To this point, a unilateral varicocele may have effects on both testicles.^{29,30}

The pathophysiology of varicoceles has been explored at the cellular level. Increased abdominal temperature results in decreased testosterone synthesis by Leydig cells, altered Sertoli cell function and morphology, injury to germinal thermolabile cell membranes, decreased amino acid transport, and decreased protein biosynthesis.³¹⁻³⁹

Diagnosis

Varicoceles are diagnosed primarily by physical examination. Patients should be examined both supine and in the standing position. While upright, patients are asked to perform the Valsalva maneuver to examine for palpable reversal of flow. Additionally, testicular measurements are taken, since there is often ipsilateral testicular atrophy. Radiographic assessments of varicoceles include venography, the doppler stethoscope, radionuclide scans such as ^{99m}Tc - Pyrophosphate, high resolution ultrasonography, and duplex ultrasonography. These studies are helpful when physical examination is inconclusive or when further documentation of a patient's condition is necessary. When indicated, we have found duplex ultrasonography to be a valuable tool in assessing for varicocele based on both vessel size and the presence of reversal of flow.

Varicolectomy

After making the correct diagnosis of a symptomatic varicocele, the urologist must decide which operative technique to employ as several approaches exist, each with their own advantages and drawbacks, Figure 1.

Laparoscopic varicolectomy requires experience and competency in laparoscopic surgery. Generally, this technique incurs a longer operating time with more expensive equipment and a potential for internal injuries. No increased efficacy has been shown in this technique,⁴⁰ and it is performed with decreasing frequency. Artery-sparing and non-artery sparing approaches have been described.

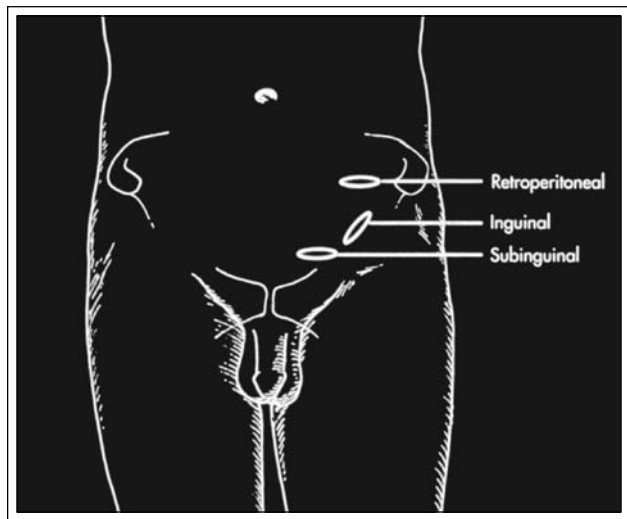


Figure 1. Open surgical approaches to varicolectomy.

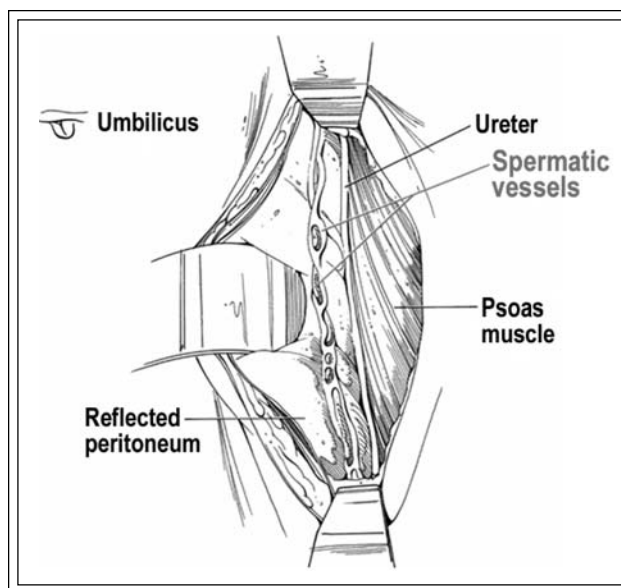


Figure 2. The retroperitoneal approach (Palomo) to varicolectomy.

The retroperitoneal approach (Palomo) requires a muscle splitting incision. The peritoneum is retracted, and the spermatic vessels are identified medial to the ureter at this level, Figure 2.⁴¹

The infrainguinal varicolectomy allows for surgical repair without a fascial incision. This approach theoretically affords the patient decreased post-operative pain, and the testicle may be delivered to allow access to the gubernacular veins. However, a significant drawback to this technique includes a higher number of smaller caliber veins to be ligated. Additionally, testicular arteries at this level tend to be end-arteries, and inadvertent ligation at this level may carry a higher risk of testicular injury. Furthermore, the benefit of gubernacular vein ligation is controversial and rapidly losing proponents, as no significant decrease in pain with this approach has been documented.

The inguinal approach (Ivanissevich) involves opening the external oblique fascia above the inguinal ring and delivering the spermatic cord into the operative field.⁴² Non-obese patients can even benefit from a 3 cm-4 cm "mini" inguinal incision.

We prefer the inguinal approach to varicolectomy, except when there is a history of previous inguinal surgery. In such cases, the subinguinal technique is employed. Routine use of an operating microscope affords easier identification of vessels and lymphatics, and the testicular artery and lymphatics are visualized and spared, Figure 3.⁴³ Additionally, it is an excellent teaching instrument. A micro Doppler probe with a

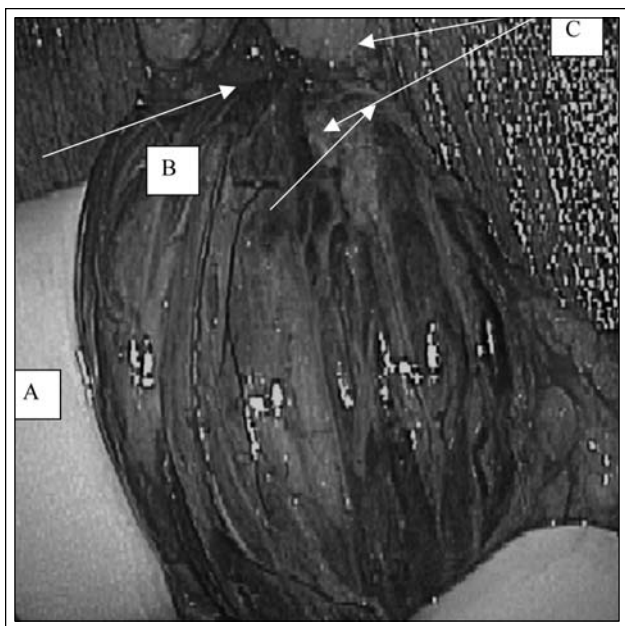


Figure 3. Spermatic cord. Large testicular vein (A), testicular artery (B), and peri-arterial veins (C), are well visualized under optical magnification.

disposable tip and a low signal-to-noise ratio Doppler box (Vascular Technology, Inc., Nashua, NH) is used on all of our cases. Using disposable Doppler tips requires less time and fewer dollars to reprocess, resulting in a highly competitive cost compared to the price of reusable devices. A micro-tip Jacobson clamp facilitates vein dissection, and veins are occluded with either 3-0 silk sutures or small hemoclips, Figures 4 and 5. Outpatient

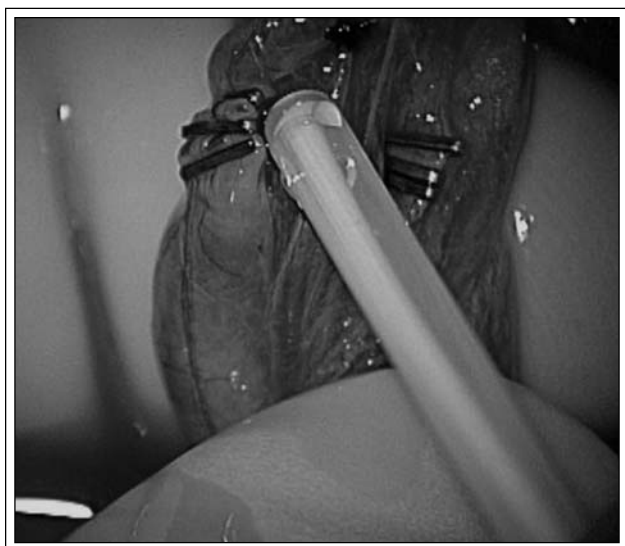


Figure 4. The micro Doppler probe is used to confirm arterial flow.



Figure 5. The micro-tip Jacobson clamp facilitates vein dissection. Veins are occluded with either 3-0 silk sutures or small hemoclips.

surgery is standard, as are peri-operative antibiotics and post-operative oral analgesics.

Outcomes

Most studies report improved semen parameters following varicocelectomy,⁴⁴ however, conflicting data exists on improved pregnancy and fertility outcomes.⁴⁵⁻⁴⁷ A meta-analysis of 22 studies included 2989 patients who underwent varicocelectomy. Seventy one percent of patients had improvements in their post-operative semen parameters, and 37% achieved pregnancy.⁴⁸ A more recent review of published controlled studies found higher pregnancy rates in couples whose men underwent varicocelectomy versus observation.⁴⁹

Conclusion

Varicocele remains the most surgically treatable form of male infertility. Knowing the correct techniques of diagnosis and surgical correction will ensure the best chance of successful outcomes in terms of post-operative morbidity, improved semen parameters, and pregnancy rates. □

References

1. Marquette CM, Koonin LM, Antarsh L, Gargiullo PM, Smith JC. Vasectomy in the United States, 1991. *Am J Public Health* May 1995;85(5):644-649.
2. Belker AM, Thomas AJ, Jr., Fuchs EF, Konnak JW, Sharlip ID. Results of 1,469 microsurgical vasectomy reversals by the Vasovasostomy Study Group. *J Urol* Mar 1991;145(3):505-511.

Vasectomy reversal: new techniques and role in the era of intracytoplasmic sperm injection

3. Belker AM, Konnak JW, Sharlip ID, Thomas AJ, Jr. Intraoperative observations during vasovasostomy in 334 patients. *J Urol* Mar 1983;129(3):524-527.
4. Witt MA, Heron S, Lipshultz LI. The post-vasectomy length of the testicular vasal remnant: a predictor of surgical outcome in microscopic vasectomy reversal. *J Urol* Apr 1994;151(4):892-894.
5. Sharlip ID, Belker AM, Konnak JW, Thomas AJ, Jr. Relationship of gross appearance of vas fluid during vasovasostomy to sperm quality, obstructive interval and sperm granuloma. *J Urol* Apr 1984;131(4):681-683.
6. Cookson MS, Witt MA, Kimball KT, Grantmyre JE, Lipshultz LI. Can semen analysis predict the presence of antisperm antibodies in patients with primary infertility? *World J Urol* 1995;13(5):318-322.
7. Kolettis PN, Thomas AJ, Jr. Vasoepididymostomy for vasectomy reversal: a critical assessment in the era of intracytoplasmic sperm injection. *J Urol* Aug 1997;158(2):467-470.
8. CDC, American Society for Reproductive Medicine aSfART. 2002 assisted reproductive technology success rates (<http://www.cdc.gov/reproductivehealth/ART02/index.htm>).
9. Karpman E, Williams DH, Lipshultz LI. IVF and ICSI in Male Infertility: Update on Outcomes, Risks, and Costs. *ScientificWorldJournal* Nov 16 2005;5:922-932.
10. Neumann PJ, Gharib SD, Weinstein MC. The cost of a successful delivery with in vitro fertilization. *N Engl J Med* Jul 28 1994;331(4):239-243.
11. Pavlovich CP, Schlegel PN. Fertility options after vasectomy: a cost-effectiveness analysis. *Fertil Steril* Jan 1997;67(1):133-141.
12. Berger RE. Triangulation end-to-side vasoepididymostomy. *J Urol* Jun 1998;159(6):1951-1953.
13. Donovan JF, Jr., DiBaise M, Sparks AE, Kessler J, Sandlow JI. Comparison of microscopic epididymal sperm aspiration and intracytoplasmic sperm injection/in-vitro fertilization with repeat microscopic reconstruction following vasectomy: is second attempt vas reversal worth the effort? *Hum Reprod* Feb 1998;13(2):387-393.